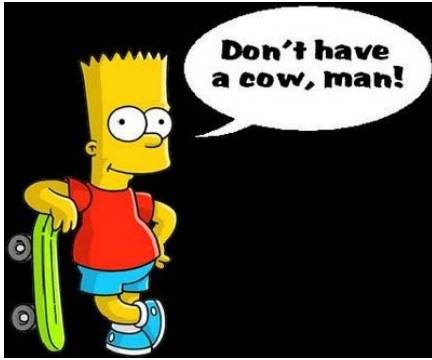

# HOLY C.O.W.!

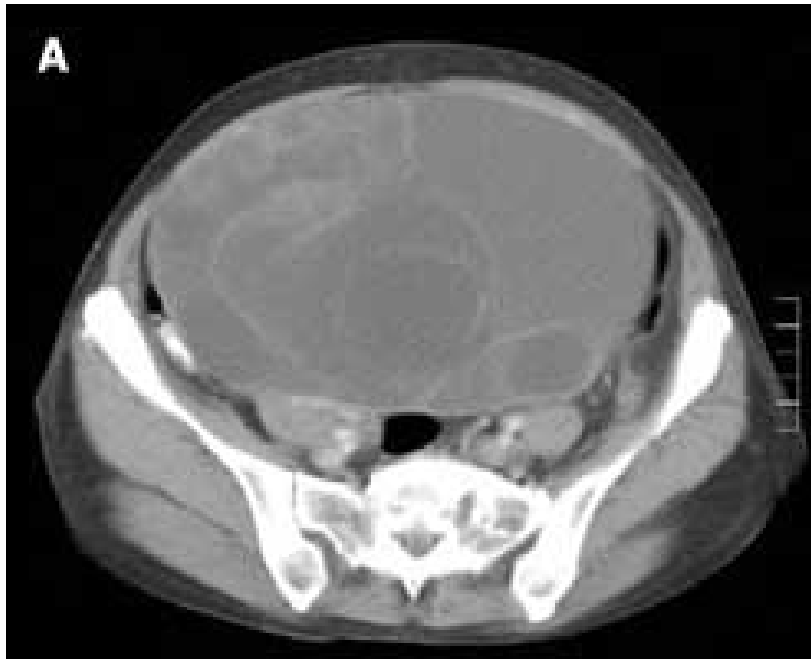
## IT'S...

Clinical Question of the Week #18  
October 27th, 2008 through November  
3rd, 2008

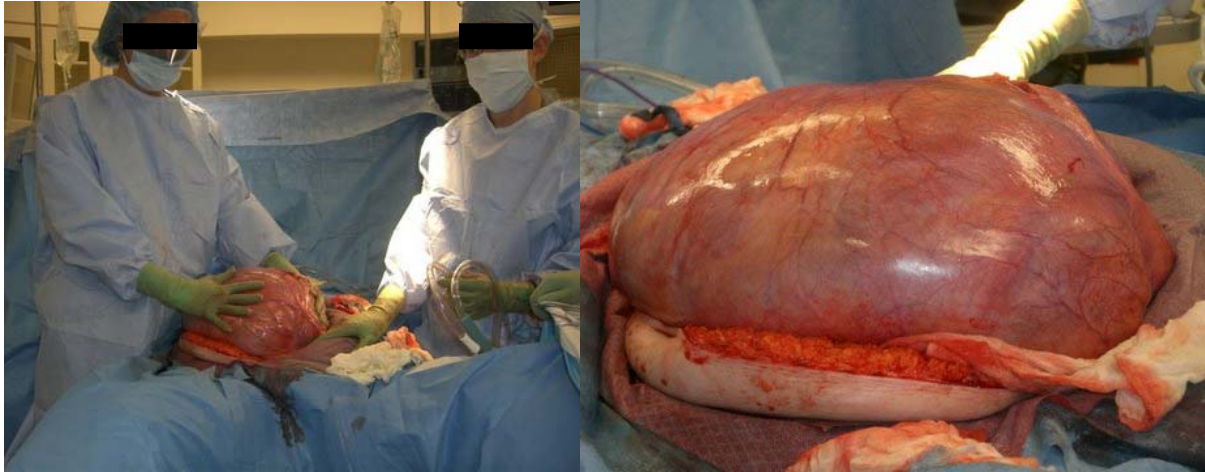


Welcome to the Halloween edition to Holy C.O.W.! Clinical Question of the Week! Please e-mail your answers to Kuo, Tim, Wendy, and Kevin ([klian@mednet.ucla.edu](mailto:klian@mednet.ucla.edu); [tprovias@mednet.ucla.edu](mailto:tprovias@mednet.ucla.edu); [wsimon@mednet.ucla.edu](mailto:wsimon@mednet.ucla.edu); [kbreger@mednet.ucla.edu](mailto:kbreger@mednet.ucla.edu)) by 0800 on Monday, November 3rd, 2008. The resident or intern with the most correct answers at the end of each month will receive a prize!

**Case:** A 36-year-old woman is brought in by police to the Emergency Department after she is found wandering the streets in a robe and slippers. At the time of interview, the patient reports histrionically that she is carrying the Devil's child. She is admitted to the Medicine service. With further interview, she also reports that she has been pregnant for several years and believes that the time is coming soon when she will deliver the child to wreak havoc on mankind. On examination, she is obese and agitated. Her abdomen is enlarged and a large mass is palpated with some discomfort. A CT abdomen/pelvis was obtained, and she subsequently underwent exploratory laparotomy (shown).



CT abdomen/pelvis



Images taken at laparotomy.

**Questions:**

1. **What is the diagnosis?**
2. **What is the origin of the mass?**
3. **Describe the findings seen on histopathology and the rough likelihood of malignancy in the mass.**
4. **What is the treatment?**