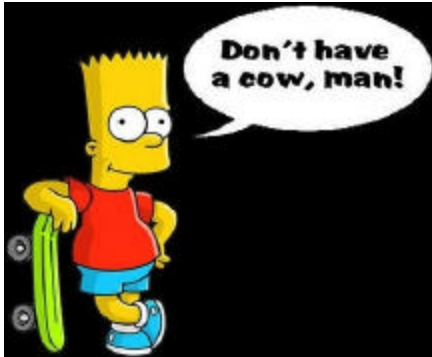



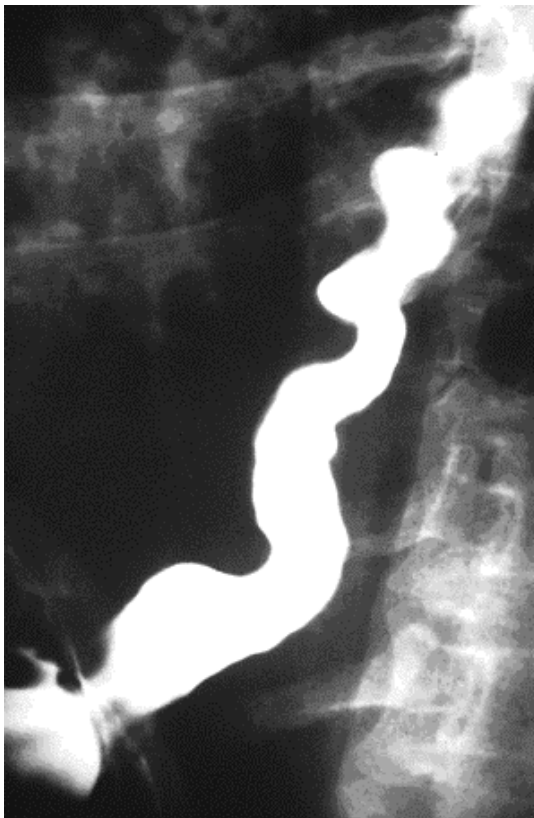
# Holy C.O.W.!

It's...

**Clinical Question of the Week #19**  
**November 3rd, 2008 through November**  
**10th, 2008**

Please e-mail your answers to Kuo, Tim, Wendy, and Kevin ([klian@mednet.ucla.edu](mailto:klian@mednet.ucla.edu); [tprovias@mednet.ucla.edu](mailto:tprovias@mednet.ucla.edu); [wsimon@mednet.ucla.edu](mailto:wsimon@mednet.ucla.edu); [kbreger@mednet.ucla.edu](mailto:kbreger@mednet.ucla.edu)) by 0800 on Monday, November 10th, 2008. The resident or intern with the most correct answers at the end of each month will receive a prize!

**Case:** A 75-year-old woman presents to the Emergency Department with chest pain for the third time in the past four months. Each time she is found to have no significant EKG changes and negative cardiac enzymes, and is discharged. Her pain subsided, however, after sublingual nitroglycerin the last two times she was seen in the ED. She underwent an adenosine myoview two years ago, which revealed no evidence of reversible ischemia. She is now admitted to the Observation service, where the intrepid resident orders an upper GI series, shown below.



Upper GI series with barium contrast

**Questions:**

1. **What is the diagnosis? What are two other related syndromes?**
2. **Name the three cardinal symptoms of this condition.**
3. **What is the finding shown in the image above?**
4. **What is the treatment?**