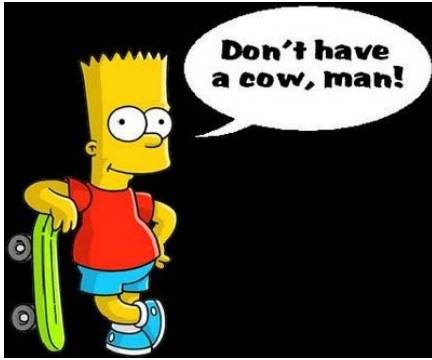

HOLY C.O.W.!

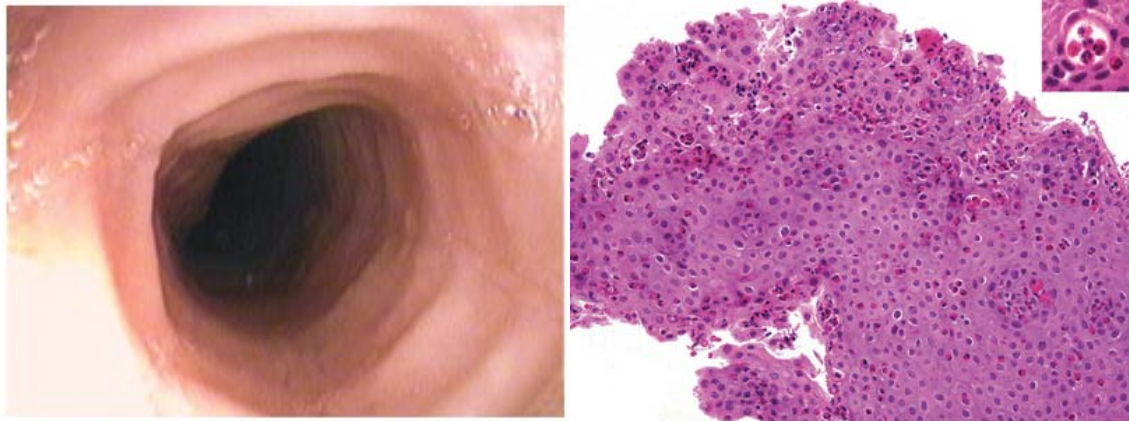
IT'S...

Clinical Question of the Week #22
November 24th, 2008 through December
1st, 2008



Welcome to the Thanksgiving edition of Holy C.O.W.! Please e-mail your answers to Kuo, Tim, Wendy, and Kevin (klian@mednet.ucla.edu; tprovias@mednet.ucla.edu; wsimon@mednet.ucla.edu; kbreger@mednet.ucla.edu) by 0800 on Monday, December 1st, 2008. The resident or intern with the most correct answers at the end of each month will receive a prize!

Case: A 62-year-old man presents to the Emergency Department for evaluation of acute retrosternal fullness and pain for the past hour, associated with some increased secretions. The patient is currently visiting his nephew, an intrepid IM resident at UCLA, and was enjoying an early holiday dinner of Turducken™, green beans, yams, and mashed potatoes. His past medical history is notable for well-controlled hypertension, GERD, and allergic rhinitis. He is allergic to PCN (rash) and peanuts; medications include HCTZ, pepcid, and occasional benadryl. In the ED, the patient was taken urgently to upper endoscopy, which revealed acute food bolus impaction. After removal of the bolus, biopsy of the esophagus was also performed. Post-procedure, the patient felt much improved and was discharged back with his family for the holiday.



The patient's upper endoscopy (food bolus removed); biopsy from esophagus with H&E stain.

Questions:

1. What is the diagnosis?
2. Describe the gross and pathologic findings depicted in the images above.
3. Name two associated symptoms or conditions.
4. What is the treatment?