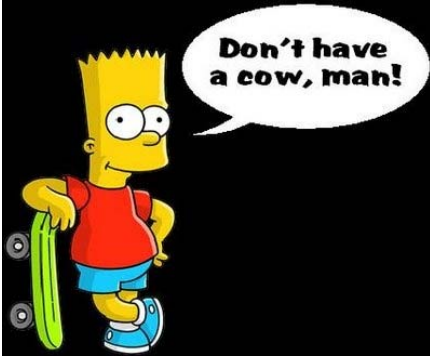

HOLY C.O.W.!

IT'S...

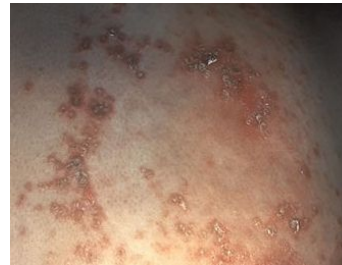Clinical Question of the Week #28
January 19th, 2009 through January 26th,
2009



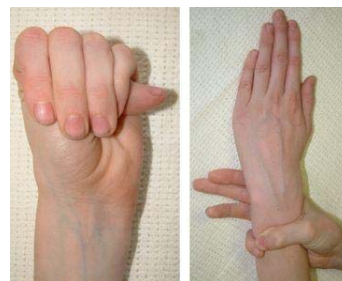
Happy Inauguration Day! Please e-mail your answers to Kuo, Tim, Wendy, and Kevin (klian@mednet.ucla.edu; tprovias@mednet.ucla.edu; wsimon@mednet.ucla.edu; kbreger@mednet.ucla.edu) by 0800 on Monday, January 26th, 2009. The resident or intern with the most correct answers at the end of each month will receive a prize!

Presidential Roundtable! Six members of a very special 44-member fraternity present into office for care with the following complaints. It's a busy clinic day, so better get hopping!

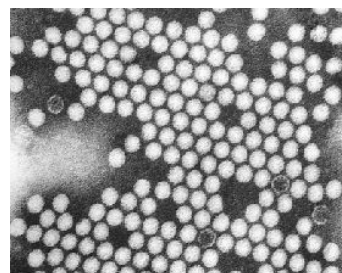
Case A: A 54-year-old man presents with subacute onset of left flank pain for three days followed by the finding shown at right over the same distribution.



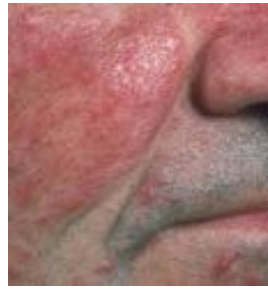Case B: A tall 52-year-old man is noted to have a systolic murmur, and is found to have the findings shown at right.



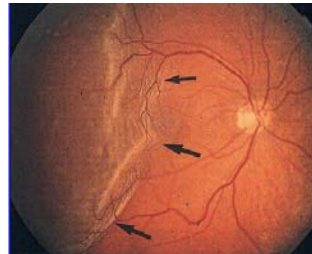
Case C: A 51-year-old man is referred for evaluation of bilateral lower extremity paresis, atrophy and contracture. The etiologic agent is shown at right.



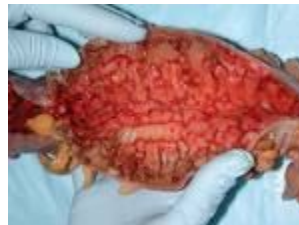Case D: A 56-year-old man presents for evaluation of redness and bumps on bilateral cheeks of his face. A photograph of a patient with similar findings is shown at right.



Case E: A 43-year-old man presents for emergent evaluation after suddenly developing floaters followed by loss of vision in the left eye during a sparring match in the ring. Findings on retinal exam are shown at right.



Case F: A 62-year-old man is taken to surgery for abdominal pain after having chronic intermittent diarrhea, which is sometimes severe and bloody. Pathology specimen taken from resected intestine is shown at right.




Questions: For each case, please name the diagnosis and the president afflicted. (0.5 given for each correct answer).

1. **Case A** – Herbert Hoover (31st president, served 3/4/1929-3/4/1933) suffered from herpes zoster.



2. **Case B** – Abraham Lincoln (16th president, served 3/4/1861-4/15/1865) was suspected to possibly have had Marfan syndrome.



3. **Case C** – Franklin Delano Roosevelt (32nd president, served 3/4/1933-4/2/1945) suffered from complications of polio myelitis. Shown is one of the few photos of Roosevelt in a wheelchair.




4. **Case D** – William Jefferson Clinton (42nd president, served 1/20/1993-1/20/2001) got his well-recognized ruddy complexion from acne rosecea.



5. **Case E** – Theodore Roosevelt (26th president, served 9/14/1901-3/4/1909) suffered a left retinal detachment during a boxing match while he was in office, ending his long boxing career and resulting in left-sided blindness.



6. **Case F** – Dwight David “Ike” Eisenhower (34th president, served 1/20/1953-1/20-1961) suffered from Crohn’s disease and underwent emergency surgery while in office for intestinal obstruction.



**For those who caught the clue in the email, each of the cases was present with the age that each President took office. In addition to the above, many presidents suffered from infectious illness, gout, coronary artery disease, congestive heart failure, and cerebral hemorrhage. For more, check out <http://www.healthinplainenglish.com/presidential-diseases/index.htm>.